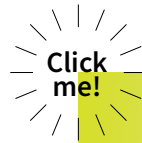

International Team for Implantology

Study Club in a Box

A photograph of a male athlete in a black singlet and shorts, captured in mid-stride during a sprint on a track. The image has a yellow tint.

Immediacy

A digital-themed image featuring a silhouette of a person's head in profile, filled with binary code (0s and 1s). The background is dark blue with glowing digital elements.

Digital

A photograph of a ballerina in a blue tutu, captured in a dynamic pose with her arms raised. The image has a teal tint.

Esthetics

A photograph of a modern building with large glass windows and a concrete structure, suggesting a foundation or base.

**Foundations
in Implant
Dentistry**

ITI Study Club in a Box

Immediacy

Back to  home



1

Immediate Implant Placement



Consensus Conference (2x)



Congress Lecture



Webinar



Clinical Case VIDEO



Clinical Case

2

Immediate Implant Loading



Consensus Conference (2x)



Forum Implantologicum



Learning Module

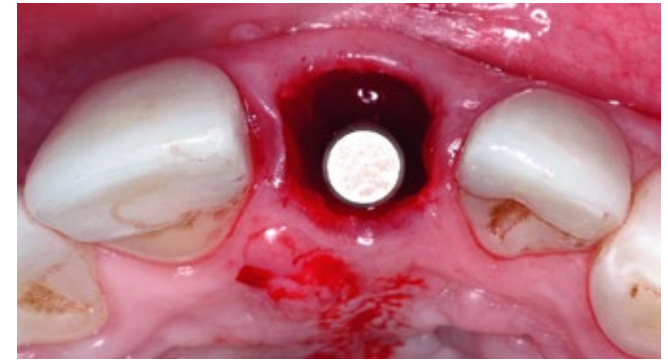


Webinar



Clinical Case (3x)

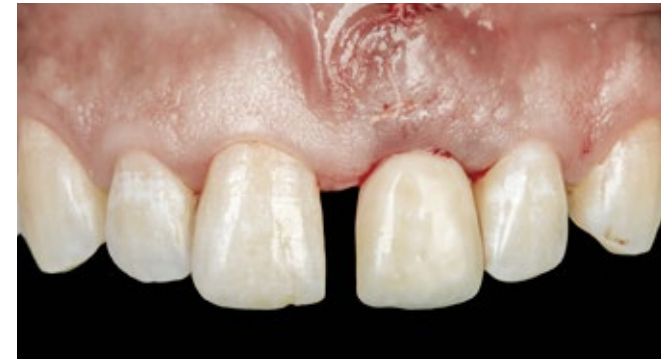Immediate Implant Placement



Picture 1. Courtesy of Dr. Eduardo Lorenzana

1.	 Consensus Conference	Implants in Post-Extraction Sites	Stephen T Chen	6 min read
2.	 Consensus Conference	Esthetic Outcomes following Immediate and Early Implant Placement in the Anterior Maxilla	Stephen T Chen	3 min read
3.	 Congress Lecture	Post-Extraction Ridge Alteration – A Risk for Esthetics	Stephen T Chen	28 min
4.	 Webinar	Post-Extraction Implant Placement: When Immediate, When Early and When Late?	Stephen T Chen	58 min
5.	 Clinical Case VIDEO	Immediate Implant Placement – Immediate Temporary Guided Surgery in the Aesthetic Zone	Nikos Mattheos	14 min
6.	 Clinical Case	Replacing Four Upper Incisors with a Screw-Retained Bridge on Two Implants	Krzysztof Chmielewski	9 min

Immediate Implant Loading



Picture 2. Courtesy of Dr. Adam Hamilton

1.	 Consensus Conference	<u>Immediate Loading vs. Early/Conventional Loading of Immediately Placed Implants in Partially Edentulous Patients from the Patients' Perspective</u>	<u>Guy Huynh-Ba</u> <u>Thomas Oates</u>	2 min read
2.	 Forum Implantologicum	<u>Early Implant Placement Following Single Tooth Extraction in the Esthetic Zone with Contour Augmentation – Selection Criteria, Surgical Procedures and Long-Term Results</u>	<u>Daniel Buser</u> <u>Vivianne Chappuis</u> <u>Simone F. M. Janner</u> <u>Urs Belser</u>	26 min read
3.	 Learning Module	<u>Immediate Restoration and Loading</u>	<u>Diego Bechelli</u>	36 min
4.	 Webinar	<u>Implant Placement and Loading Protocols in Partially Edentulous Patients: Findings from the 6th ITI Consensus Conference</u>	<u>Adam Hamilton</u>	1h 14min
5.	 Clinical Case	<u>Immediate Loading of an Anterior Implant with a Prefabricated Crown</u>	<u>Adam Hamilton</u>	9 min
6.	 Clinical Case	<u>Replacing Four Upper Incisors with a Screw-Retained Bridge on Two Implants</u>	<u>Krzysztof Chmielewski</u>	9 min
7.	 Clinical Case	<u>Replacing Three Mandibular Posterior Teeth with an Immediately Loaded Fixed Dental Prosthesis</u>	<u>Wiebe Derksen</u>	9 min

Digital

1

Digital Impression and Digital Treatment Planning



Consensus Conference



Forum Implantologicum



Congress Lecture



Clinical Case

2

Digital Implant Prosthodontics



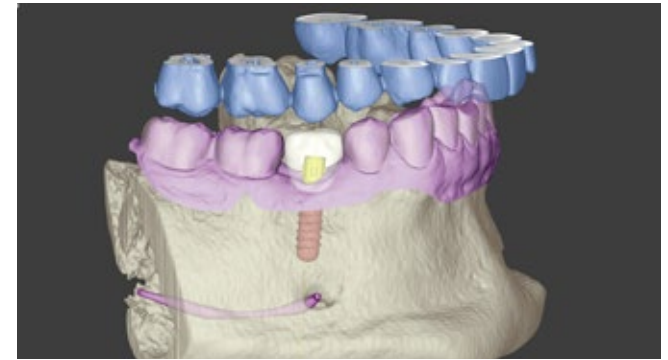
Forum Implantologicum (3x)



Webinar (2x)



Digital Impression and Digital Treatment Planning



Picture 3. Courtesy of Dr. Tim Joda

1.	 Consensus Conference	<u>Accuracy of Different Dental Impression Techniques for Implant-Supported Dental Prostheses</u>	<u>Tabea Flügge</u> <u>Daniel Wismeijer</u> <u>Ping Wang</u>	2 min read
2.	 Forum Implantologicum	<u>Pre-Operative Analysis and Treatment Planning in Digital Implant Dentistry</u>	<u>Florian Kernen</u> <u>Tabea Flügge</u>	16 min read
3.	 Congress Lecture	<u>Digital Approach to Implant Dentistry</u>	<u>German Gallucci</u>	59 min
4.	 Clinical Case	<u>Replacing a Mandibular Second Premolar with a Chairside-Fabricated Crown</u>	<u>Tim Joda</u>	9 min

Digital Implant Prosthodontics



Picture 4. Courtesy of Dr. Tim Joda

1.	 Forum Implantologicum	<u>Variables Affecting the Accuracy of Static Computer-Assisted Implant Surgery: Bridging the Gap Between Clinical Success and Broad Application</u>	<u>Karim El Kholy</u> <u>Simone F. M. Janner</u> <u>Ramona Buser</u> <u>Daniel Buser</u>	16 min read
2.	 Forum Implantologicum	<u>Computer-Assisted Implant Surgery (CAIS) and Available Surgical Tools in Daily Practice: Clinical Experience</u>	<u>Ali Tahmaseb</u> <u>Jobine te Poel</u> <u>Daniel Wismeijer</u>	13 min read
3.	 Forum Implantologicum	<u>Current State of CAD/CAM Technology in Implant Dentistry</u>	<u>Dean Morton</u> <u>Waldemar D. Polido</u> <u>Wei-Shao Lin</u>	10 min read
4.	 Webinar	<u>Digitally assisted implant prosthodontics – all the tips and tricks you need to know</u>	<u>German Gallucci</u>	59 min
5.	 Webinar	<u>Restorative Dentistry in Times of Digitalization</u>	<u>Irena Sailer</u>	57 min

Esthetics

1

Implant Placement & Restoration in the Esthetic Zone



Consensus Conference (3x)



Forum Implantologicum (2x)



Congress Lecture



Webinar



Clinical Case (2x)

2

Soft Tissue Management in the Esthetic Zone



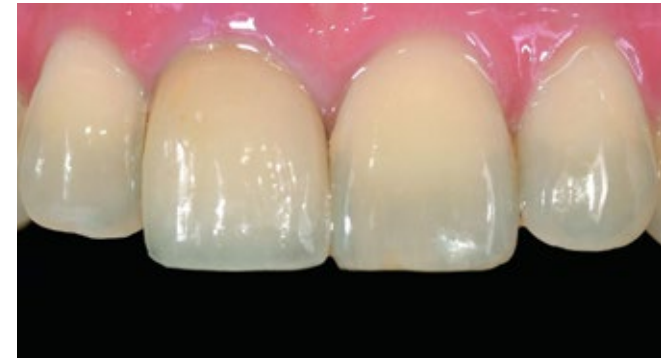Consensus Conference (2x)



Clinical Case (2x)



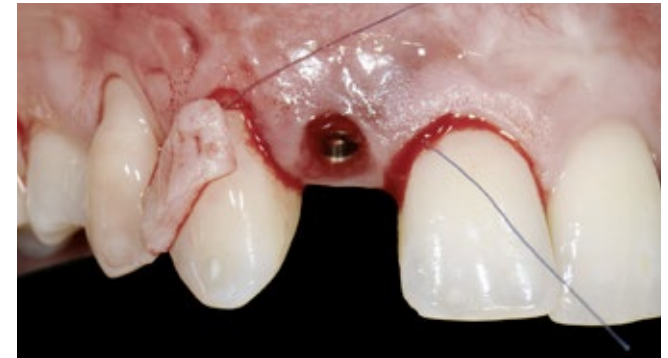
Implant Placement & Restoration In The Esthetic Zone



Picture 5. Courtesy of Dr. Chatchai Kunavisarut

1.	 Consensus Conference	Influence of Restorative Procedures on Esthetic Outcomes	William Martin Adrien Pollini Dean Morton	2 min read
2.	 Consensus Conference	Esthetics in Implant Dentistry		3 min read
3.	 Consensus Conference	Esthetic Outcomes following Immediate and Early Implant Placement in the Anterior Maxilla	Stephen T Chen	2 min read
4.	 Forum Implantologicum	The Benefits and Limitations of Zirconia as a Restorative Material for Fixed Restorations Supported by Dental Implants: A Current Status	Laurent Marchand	15 min read
5.	 Forum Implantologicum	Clinical Variables for Successful Esthetic Outcomes of Implant Prosthodontics	Ignacio Pedrinaci Elli Kotina Neil Griseto Adam Hamilton German O. Gallucci	9 min
6.	 Congress Lecture	Interdisciplinary Esthetic Approach	Diego Bechelli	15 min
7.	 Webinar	Esthetic Risk Assessment in Implant Dentistry in Partially Edentulous and Edentulous Patients	William Christopher Martin	1 h
8.	 Clinical Case	Replacement of an Upper Right Central Incisor with a Root Fracture, Early Placement of an RC Bone Level Implant, Variobase Abutment	Chatchai Kunavisarut	9 min
9.	 Clinical Case	Replacement of an Ankylosed Central Incisor with a Gingival Recession: Tooth Extraction with Socket Grafting and Late Implant Placement with Simultaneous Contour Augmentation	Daniel Buser	9 min

Soft Tissue Management In The Esthetic Zone



Picture 6. Courtesy of Dr. Paolo Casentini

1.	 Consensus Conference	<u>Soft Tissue Augmentation Procedures for Mucosal Defects in the Esthetic Zone</u>	<u>Robert Alan Levine</u> <u>Guy Huynh-Ba</u> <u>David L Cochran</u>	2 min read
2.	 Consensus Conference	<u>Esthetic Outcomes following Immediate and Early Implant Placement in the Anterior Maxilla</u>	<u>Stephen T Chen</u> <u>Daniel Buser</u>	3 min read
3.	 Clinical Case	<u>Periodontal Plastic Surgery and Prosthetic Procedures to Treat Peri-Implant Soft-Tissue Dehiscences</u>	<u>Paolo Casentini</u>	15 min read
4.	 Clinical Case	<u>Early Implant Placement, Contour Augmentation, and Autologous Connective-Tissue Graft Using a Tunneling Technique to Replace an Upper Incisor with Generalized Gingival Recession</u>	<u>Eduardo R Lorenzana</u> <u>Jason Gillespie</u>	15 min read

ITI Study Club in a Box

Back to  home



Foundations in Implant Dentistry

1

Surgical Concepts



Learning Module



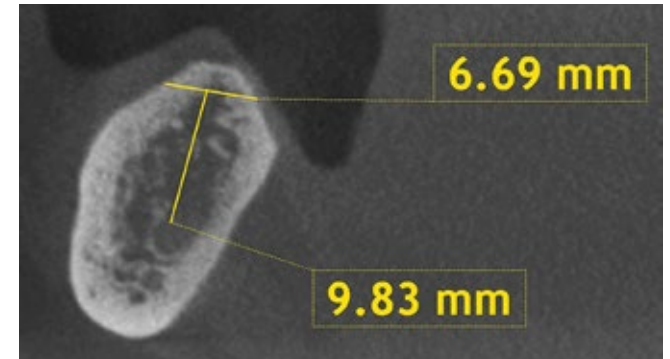
Congress Lecture



Clinical Case (2x)

Click
me!

Surgical Concepts



Picture 7. Courtesy of Dr. Paolo Casentini

1.		Learning Module	Flap Design	Merete Aaboe	21 min
2.		Learning Module	Flap Closure	Aileen Bell	32 min
3.		Learning Module	The SAC Classification	Anthony S Dawson	21 min
4.		Congress Lecture	Minimally Invasive Approach to Minimize Surgical Complications	France Lambert	30 min
5.		Clinical Case	Replacement of a Maxillary Left First Molar Using an Early Loading Protocol	Daniel Buser	9 min
6.		Clinical Case	Rehabilitation of a Mandibular Distal Extension Situation in a 89-year-old Patient with an Implant-supported Fixed Dental Prosthesis	Daniel Buser	9 min